

**PATIENT**

Phillip Moise

**SPECIES**

Feline

**BREED**

DLH

**SEX**

Male Neutered

**AGE**

1.25.08

**WEIGHT**

14.3lbs

**INTERPRETED BY**Maggie Machen Lamy,  
DVM, DACVIM  
(Cardiology)**HOSPITAL NAME**Churchville Veterinary  
Clinic**REFERRING VET**

Dr. Uhland

**INVOICE**

26570

**DATE**

9.26.22

**PRESENTING CLINICAL SIGNS**

History: BNP elevated. No clinical signs. No murmur noted on exam.

-Pertinent abnormal PE/Chem/CBC/UA Results: Azotemia- Crea 4.1, SDMA 18, BUN 54, ProBNP 525, T4 WNL 2.3.

-Current medications: Dasuquin daily, Gabapentin before grooming appointments (for suspected OA not aggression).

-Sedation used: Not required to complete full diagnostic ultrasound.

-Pertinent previous ultrasound results: No previous.

-STAT: Not requested

-Imaging performed by: Andi Parkinson

**ECHOCARDIOGRAM FINDINGS**

2D, m-mode, color flow and doppler imaging is available. The left ventricular wall thickness is irregular with a focal septal thickening and a minimal free wall hypertrophy. A mid-LV obstruction is identified on color flow imaging. There is a diffusely hyperechoic endocardium consistent with fibrosis. Mild symmetric papillary muscle hypertrophy and remodeling. The right ventricle is subjectively normal in size and morphology. There is no left atrial enlargement present. No right atrial enlargement present. Normal RVOT velocity. Trace TR. Normal LVOT velocity. There is no obvious systolic anterior motion (SAM) of the mitral valve present. No MR. There is no pericardial effusion noted. No pleural effusion appreciated. No obvious cardiac tumors.

**CARDIAC CHART**

FELINE CARDIAC PARAMETERS	BODY WEIGHT (kg)	HR (BPM)	IVSd (cm) <small>(Moise, Pipers)</small>	LVIDd (cm) <small>(Moise, Pipers)</small>	LWVd (cm) <small>(Moise, Pipers)</small>	FS (%)	EF (%)
NORMAL PARAMETER	-----	150-240	3.5-0.55	<2 (mean 1.5)	3.5-0.55	35-67	80-100
PATIENT	6.5	NM	0.73	1.6	0.59	58	92
FELINE CARDIAC PARAMETERS	LA/AO <small>(Boon)</small>	LA/AO HEART BASE (Swe) <small>(Abbott)</small>	LA 2D short axis Base view (cm) <small>(Abbott)</small>	LVOT VEL (m/s)	RVOT VEL (m/s)	E max (m/s)	
NORMAL	<1.5	<1.3	<1.2	<1.6	<1.3	<0.9	
PATIENT	NM	1.2	1.1	1.1	0.71	NM	
Adapted from June Boon, Veterinary Echocardiography, 1998 Abbott J & MacLean H JVIM 2006;20: 111-119, Moise et al. Am J Vet Res 47:1476, 1986. Pipers et al. Am J Vet Res 40:882, 1979.							

## INTERPRETATION OF THE FINDINGS & FURTHER RECOMMENDATIONS

Hypertrophic cardiomyopathy (HCM) is a rule out diagnosis once a patient is deemed normotensive and euthyroid. Both should be ruled out in this case as contributing factors. The degree of disease is mild, with only mild asymmetric LVH and no LA dilation. This would indicate the risk for clinical issues is low at this time. A mid-LV obstruction is identified, which may cause a murmur depending on heart rate. No additional issues are identified.

No medications are indicated prior to significant atrial dilation. It is important to note that no medications have been shown to definitively alter long term outcome at this stage, particularly in the absence of SAM.

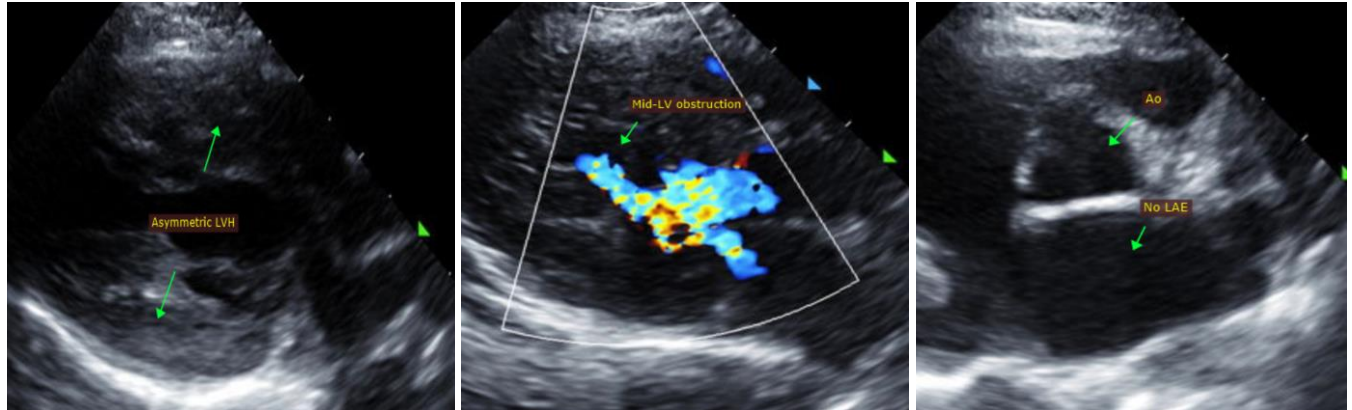
Monitor at home for any respiratory issues or signs of blood clot events (neurologic change, paralysis, etc.). Anesthetic risk is considered mild, however judicious fluid administration is advised if needed with careful RR/RE monitoring to screen for fluid overload. Additionally, drugs that stimulate heart rate should be avoided unless clinically necessary (glycopyrrolate, atropine). Risk for complication with steroid use typically follows LA dilation, which in this case is mildly elevated. If needed, monitoring of RR/RE is advised particularly in the initiation phase.

## PLAN

A screening blood pressure and T4 are recommended, then every 6 months lifelong.

A recheck echocardiogram is recommended in 6 months to assess for progression, sooner if any issues arise in the interim.

## IMAGES



**The information and recommendations provided are based on the images presented by the referring veterinarian. No evaluation can be communicated regarding pathology that was not visible in the image/video clips provided.**

Thank you for this referral. This report was generated using transcription software, and minor dictation errors may be present. If the clinical or image interpretation does not parallel your findings or if I can be of any further assistance, please contact me.

**Maggie Machen Lamy, DVM**  
**Diplomate of the American College of Veterinary Internal Medicine (Cardiology)**  
**info@sonopath.com**